



PATIENT

Winnie King

SPECIES

Feline

BREED

DSH

SEX

FS

AGE

6.5yr

WEIGHT

5.6lb

INTERPRETED BY

R. McKenzie Daniel,
DVM, DABVP
(Canine and Feline)

IMAGING PERFORMED BY

Emily Kirk

HOSPITAL NAME

Shiloh Animal Hospital

REFERRING VET

Emily Kirk

INVOICE

24914

DATE

05/22/2026

PRESENTING CLINICAL SIGNS

Patient has historically been thin natured but maintained weight over 6 pounds until October 2025. Various diets were trialed without success in getting patient to gain weight. Blood work in April 2026 showed ALP 97 (12-59). CBC and chemistry were otherwise unremarkable. Fecal nps. GI panel showed mildly low folate levels but normal cobalamin, TLI and PLI.

Abnormal PE/Chem/CBC/UA Results: See history

ULTRASONOGRAPHIC EXAMINATION OF THE ABDOMEN

Urinary System

The urinary bladder, trigone, cystourethral junction, and visible pelvic urethra to a depth of 2 cm exhibited normal thickness and tone. Anechoic urine was present in the lumen with no evidence of urine/lumen sediment, mineral, or calculi. The ureteral papillae were normal. The ureters were not visible which is normal. No evidence of inflammatory or neoplastic changes was noted.

Normal size and margination were present in the kidneys. A normal 1:3 cortex / medulla ratio and normal corticomedullary definition were maintained. The echogenicity of the cortex was similar to or slightly less than normal liver parenchyma while the medulla echogenicity was hypoechoic to the cortex with no evidence of pelvic dilation. The left kidney measured 3.7 cm in length. The right kidney measured 3.5 cm in length.

The area of the aortic trifurcation was free of pathology.

Adrenal Glands

The left adrenal gland was uniform in size and contour with a uniformly hypoechoic parenchyma. The left adrenal gland measured 0.4 cm width. The right adrenal gland was uniform in size and contour with a uniformly hypoechoic parenchyma. The right adrenal gland measured 0.35 cm width.

Spleen

The spleen exhibited a finely textured and homogenous parenchyma which was hyperechoic to the liver and renal cortical parenchyma. The capsule was smooth and regular without apparent expansion. The splenic vasculature at the hilus was normal in volume with no evidence of congestion or thrombosis. Acute to chronic inflammatory, neoplastic, or benign parenchyma changes were not noted. The spleen measured 0.7 cm in width at the level of the mid spleen.

Liver/Gallbladder

The liver was subjectively normal in size, structure, and contour. The liver parenchyma was uniform and hypoechoic to the spleen with a mild coarse echotexture. Normal vascular volume. The hepatic and portal vasculature were normal in appearance without signs of congestion. The gallbladder was non-distended in size with thin walls and minor non-organized debris. The cystic and common bile ducts were normal.

Gastrointestinal

The stomach presented intact wall layering with a normal wall layer ratio. The lumen of the stomach was empty with no signs of ileus, obstruction or foreign material.



PATIENT

Winnie King

SPECIES

Feline

BREED

DSH

SEX

FS

AGE

6.5yr

WEIGHT

5.6lb

INTERPRETED BY

R. McKenzie Daniel,
DVM, DABVP
(Canine and Feline)

IMAGING PERFORMED BY

Emily Kirk

HOSPITAL NAME

Shiloh Animal Hospital

REFERRING VET

Emily Kirk

INVOICE

24914

DATE

05/22/2026

The small intestine presented intact wall layering with 1:3 muscularis/mucosa ratio. The lumen of the small intestine was empty with no signs of mechanical/metabolic ileus, obstruction or foreign material. The jejunum wall measured 0.22 cm width. The ileocolic wall measured 0.27 cm width.

Normal visible colon wall layers were present with apparent formed feces in lumen.

Pancreas

The parenchyma of the left limb, body and right limb of the pancreas presented isoechoic to the adjacent omental fat. A normal curvilinear capsule contour of the pancreas was present. The visible pancreatic duct was normal. No signs of active inflammation or neoplastic disease was evident.

Free Abdomen

No omental masses, overt lymphadenopathy or peritoneal effusion was present.

ULTRASONOGRAPHIC FINDINGS

Primary

- Sonographically gastrointestinal tract
- Mild gallbladder debris

INTERPRETATION OF THE FINDINGS & FURTHER RECOMMENDATIONS

No evidence of visceral specifically gastrointestinal pathology, as an obvious cause of the patient's clinical history. The gallbladder debris is non-specific and potentially incidental given no hepatic enzyme elevations yet at times may be associated with cholestasis or low grade hepatobiliary inflammation given short half-life of hepatic enzymes in cats. Monitoring of liver enzymes is suggested.

For an additional charge, internal medicine consult can be utilized through SonoPath.com. You can select the internal medicine drop down at <http://spa.sonopath.com/>.

One of the world's top internists & SonoPath associate Dr. Remo Lobetti BVSc, MMedVet, PhD, DECVIM can evaluate your case through SonoPath. <https://sonopath.com/resources/sonopath-services/internal-medicine-teleconsultation-services>



PATIENT

Winnie King

SPECIES

Feline

BREED

DSH

SEX

FS

AGE

6.5yr

WEIGHT

5.6lb

INTERPRETED BY

R. McKenzie Daniel,
DVM, DABVP
(Canine and Feline)

IMAGING PERFORMED BY

Emily Kirk

HOSPITAL NAME

Shiloh Animal Hospital

REFERRING VET

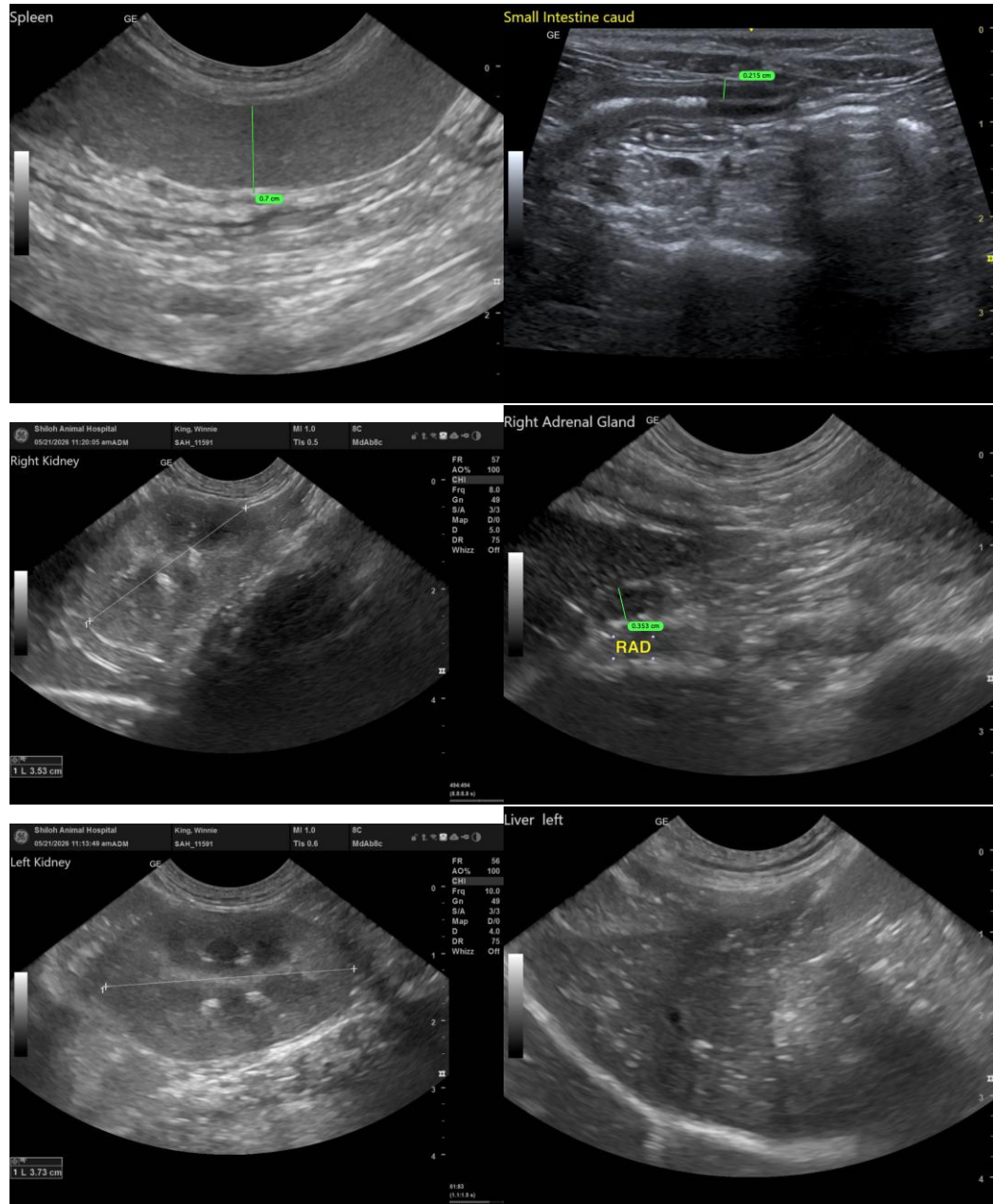
Emily Kirk

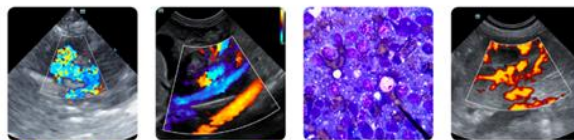
INVOICE

24914

DATE

05/22/2026





PATIENT

Winnie King

SPECIES

Feline

BREED

DSH

SEX

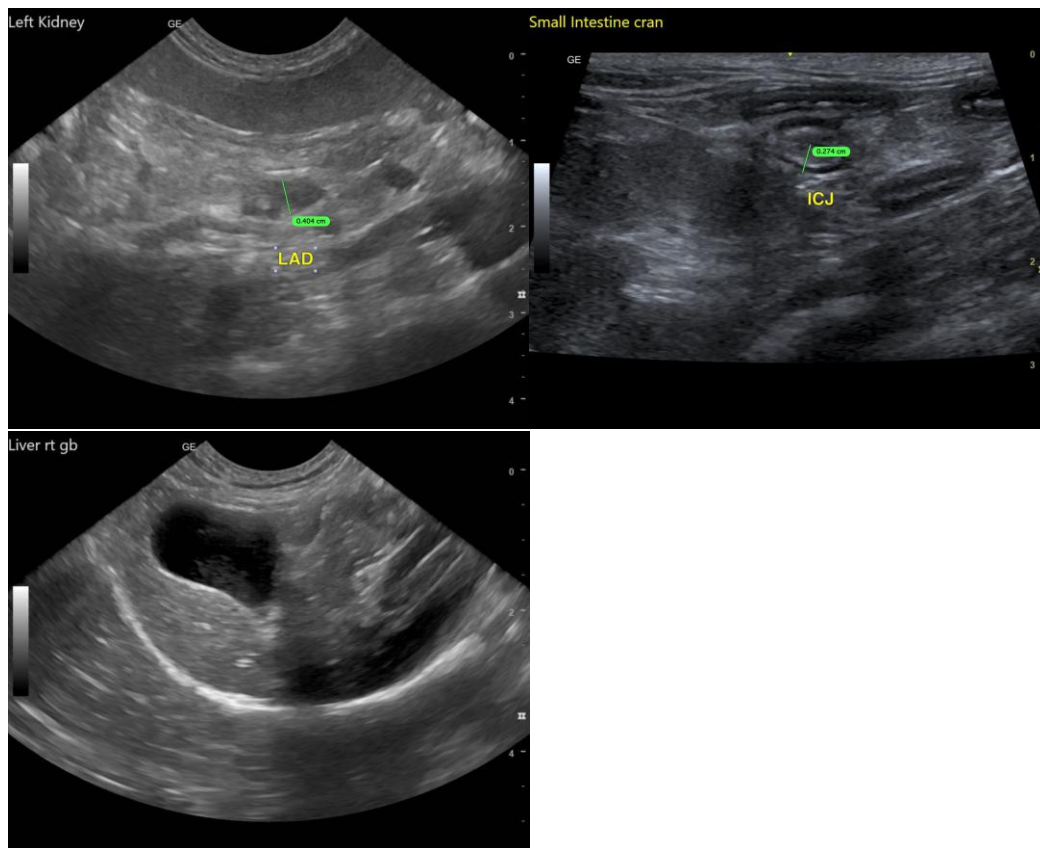
FS

AGE

6.5yr

WEIGHT

5.6lb



INTERPRETED BY

R. McKenzie Daniel,
DVM, DABVP
(Canine and Feline)

IMAGING PERFORMED BY

Emily Kirk

HOSPITAL NAME

Shiloh Animal Hospital

REFERRING VET

Emily Kirk

INVOICE

24914

DATE

05/22/2026

The information and recommendations provided are based on the images presented by the referring veterinarian/sonographer. No evaluation can be communicated regarding pathology that was not visible in the image/video clips provided.

Thank you for this referral. If the clinical or image interpretation does not parallel your findings or if I can be of any further assistance, please contact me.

R. McKenzie Daniel, DVM, DABVP (Canine/Feline Practice)
info@sonopath.com